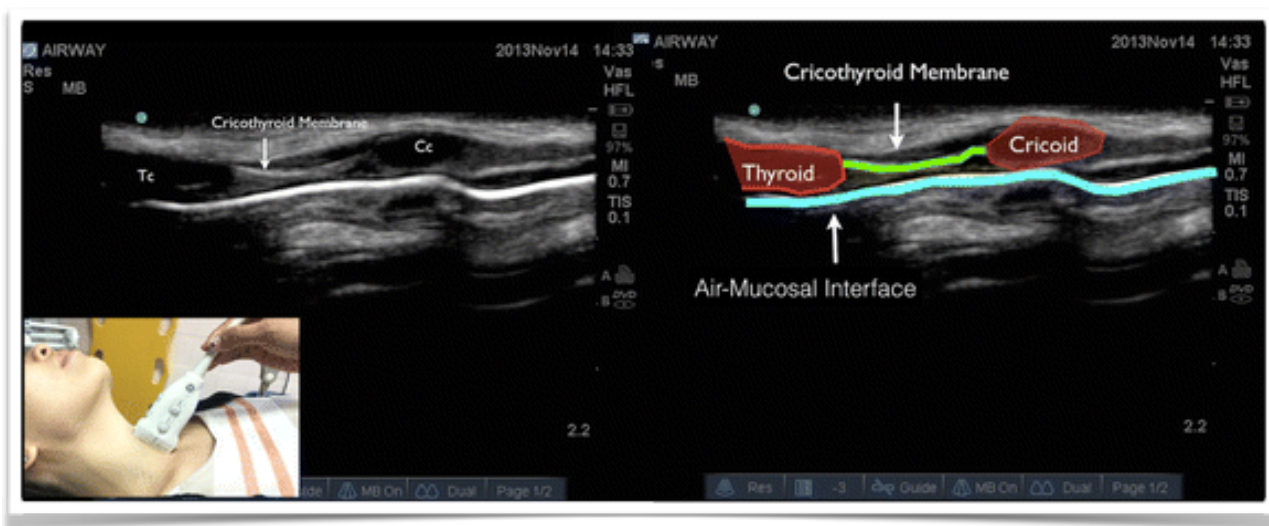


SONIC BOOM

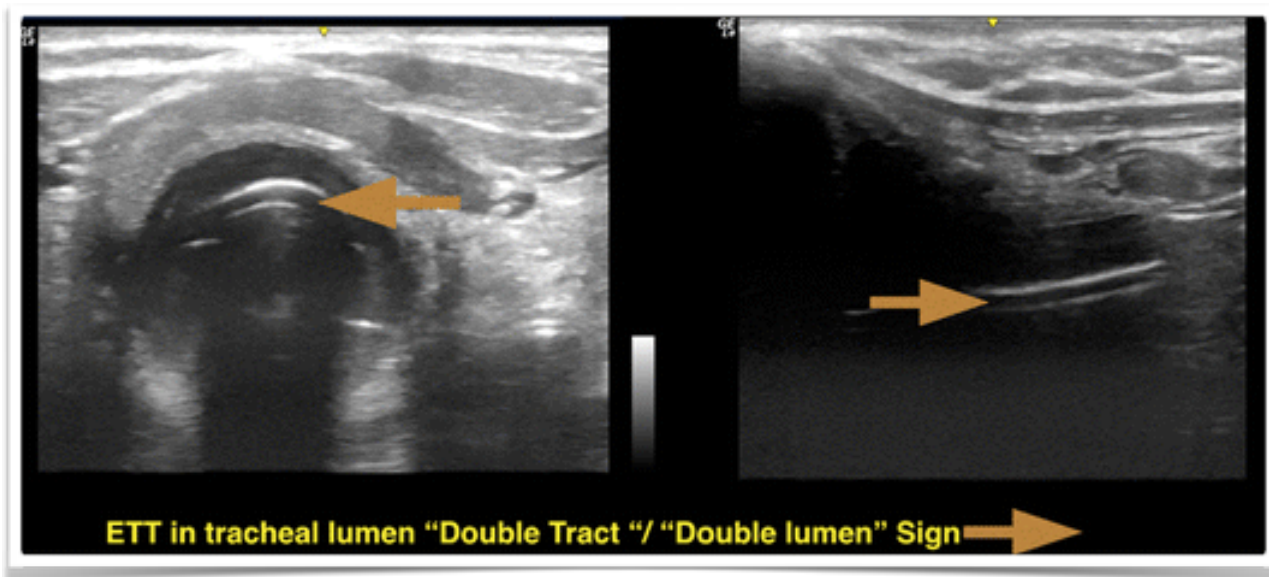
Cricothyroid Membrane for Surgical Airway

Ultrasound is a very useful tool for marking out the precise location of the cricothyroid membrane esp in the anticipated difficult airway patient. Best part is that you will be able mark the location in the position that you like and re-check esp in patients with a thick neck or decreased mobility. Apply the linear probe to the midline neck with marker pointing to the patient's head. The Thyroid and Cricoid cartilages appear hypo echoic (black), the tissue in-between being the cricothyroid membrane (1).



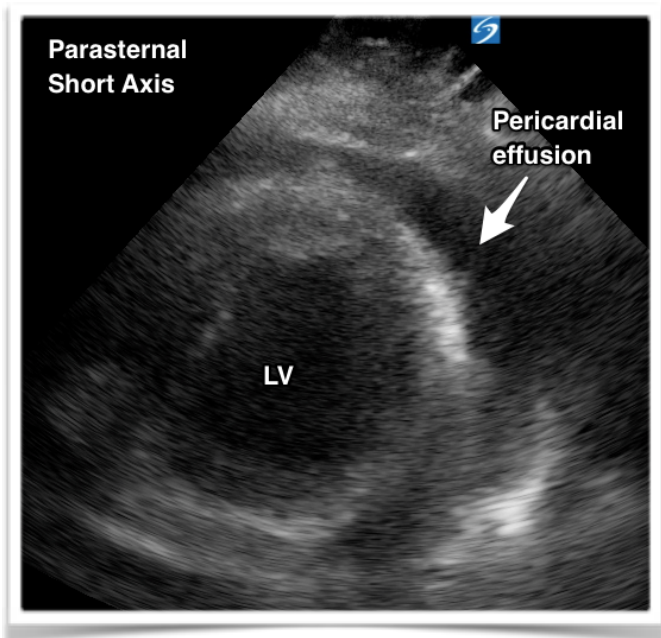
ETT placement Confirmation

ETT position in trachea is seen as two hyperechoic lines which is described as “double tract” or “double lumen” sign. This is handy when capnography or ETCO₂ are unreliable or faulty (1).



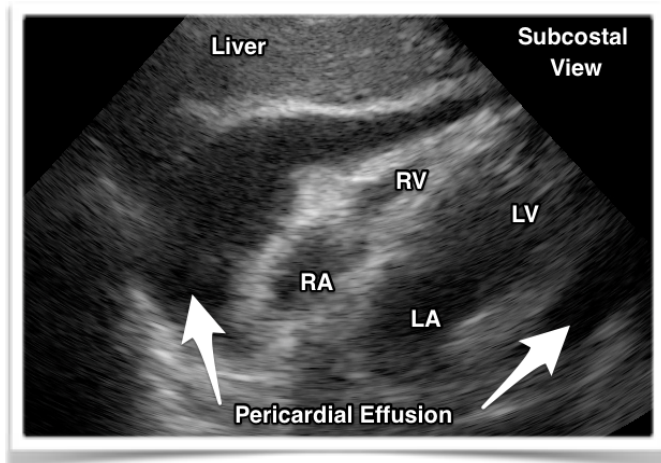
Tamponade Echo

This middle aged lady presented with a malignant pericardial effusion with a lot of controversy between Oncology, ED, Cardiology and ICU as to whether this was tamponade and when to drain it.



Features on Echo of Tamponade include:

- ▶ Pericardial Effusion - Size + Speed of formation
- ▶ Early diastolic RV collapse
- ▶ Late diastolic Atrial collapse
- ▶ Exaggerated tricuspid and decreased mitral diastolic inflow on inspiration
- ▶ IVC dilated and no variation with respiration.

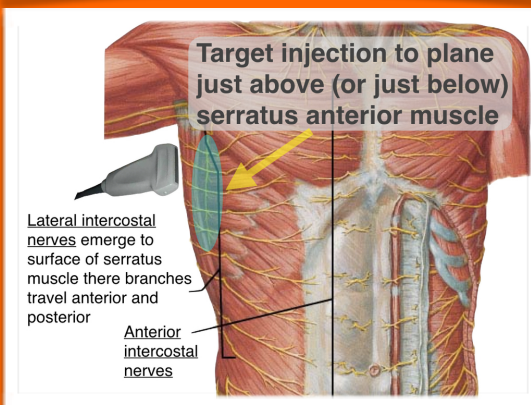
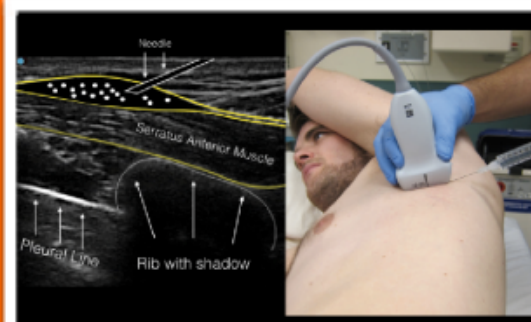
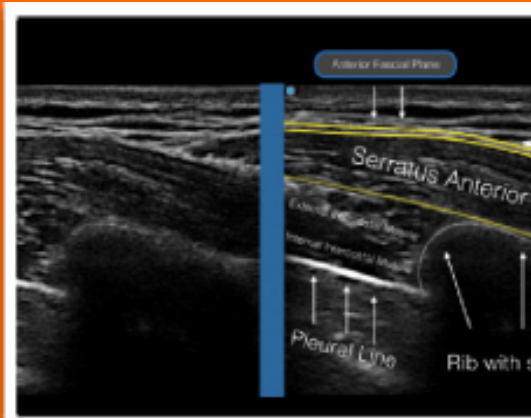


References

(1) Role of upper airway ultrasound in airway management. Osman A, Kok Meng Sum. *Journal of Intensive Care* 2016 4:5

(2) Ultrasound-Guided Serratus Anterior Plane Block Can Help Avoid Opioid Use for Patients with Rib Fractures. Arun Nagdev,

Serratus Anterior Block for Rib Fractures



Do this for your next rib fracture patient, and they will be eternally grateful - position them in Lateral Decubitus with linear probe set on 'MSK' parameters. Visualise the rib with intercostal space and underlying pleura. Keep the needle in view the whole time and infiltrate in the plane above or below the serrates which overlies the ribs (2).