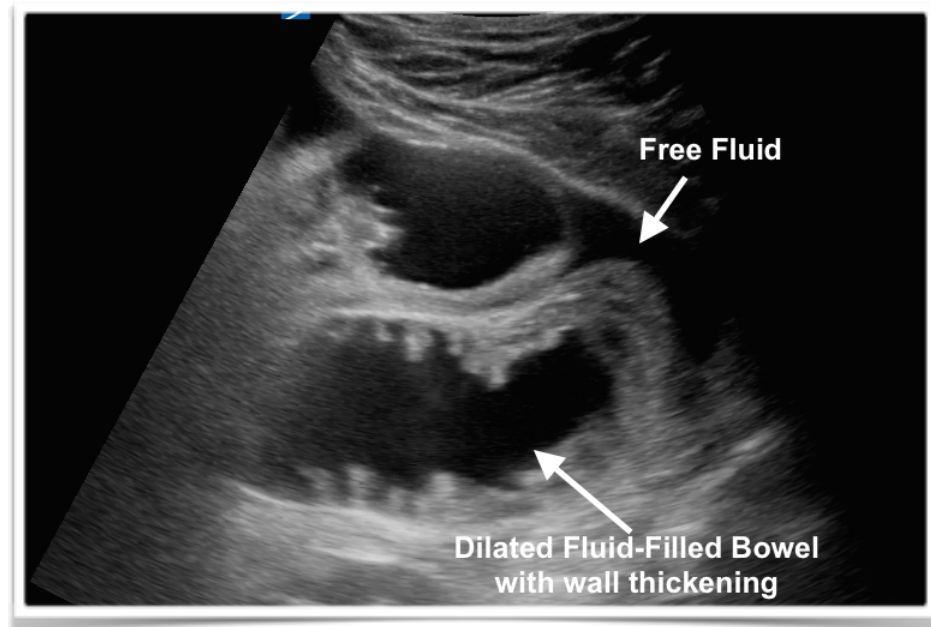

# SONIC BOOM

## Ultrasound Newsletter no: IO

Abrar Waliuddin

Saving lives and changing minds  
- one scan at a time

Image above was taken from an acutely unwell patient with multiple possible differential diagnoses. Hx of CLL, AAA mycotic aneurysm repair with allograft, IHD and CRF. A focused scan for AAA, Echo and Abdomen was performed. Images were diagnostic of SBO with suspicion for Ischaemic Bowel at the bedside - close to 90mins before CT Abdomen was performed and supported the US diagnosis. Ultrasound cleared the path to diagnosis - expediting immediate management, surgical referral and theatre planning.

### **Ultrasound findings suggestive of small bowel obstruction:**

- ✦ dilated bowel loop (diameter >2.5 cm)
- ✦ decreased bowel peristalsis

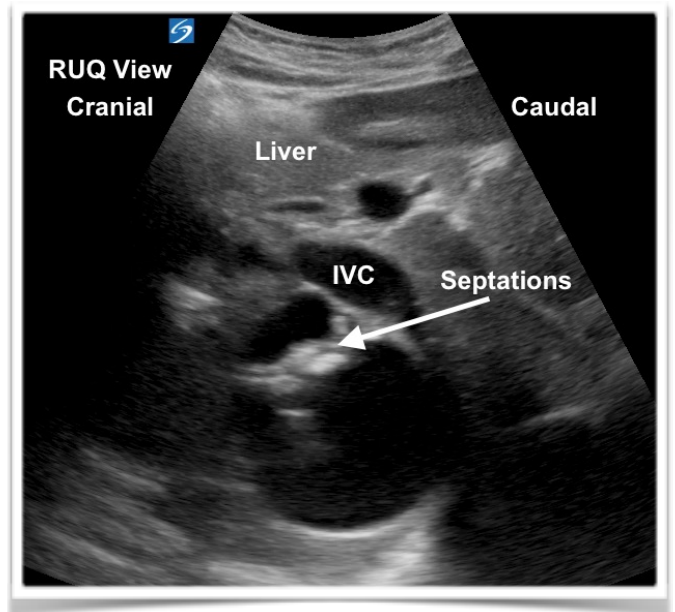
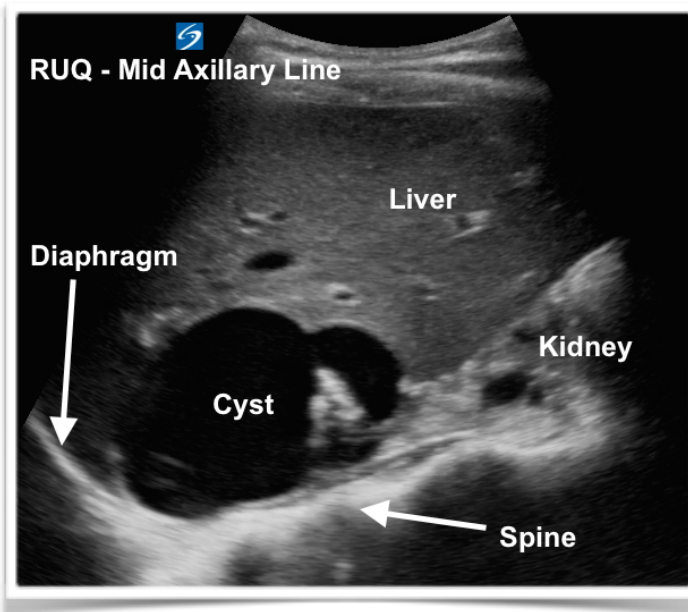
### **Ultrasound findings suggestive of bowel ischaemia/infarction:**

- ✦ fluid-filled distended bowel with extraluminal free fluid between bowel loops
- ✦ no peristalsis
- ✦ bowel wall thickening >3 mm

## Incidentaloma

32yo female with RUQ abdo pain, Mildly Raised Bilirubin, Chronic diarrhoea, Eosinophilia and past hx of Cholecystectomy. What does the image below show?? Is it hepatic or renal? Is it an abscess? Is it a cyst? Haemangioma?

Beside US showed a slightly complex septated, cystic lesion. This was closely associated with the IVC and superior pole of the Right Kidney.



Formal US agreed with my assessment that this looked like a Liver Cyst (same structure noted on US 6 yrs ago but much smaller) . This contradicts CT Abdomen report suggesting this was an Adrenal Cyst - with parasitic cyst as one of the possible diagnoses. The abdo pain is likely sec to stretching and mass effect from enlarging cyst. Patient currently an inpatient awaiting further investigations.....

**Appendicitis below** - can never have enough of it. Word.

